

## Clinical Presentation of Cholesteatoma- A Study of 50 Cases

Khan MA<sup>1</sup>, Asaduzzaman AKM<sup>2</sup>, Islam MT<sup>3</sup>, Ahmed B<sup>4</sup>, Hossain MK<sup>5</sup>, Sumon MMAK<sup>6</sup>, Rabbani SMG<sup>7</sup>

### Abstract

**Introduction:** Cholesteatoma is an abnormal accumulation of keratin-producing squamous epithelium in the middle ear, epitympanum, mastoid or petrous apex. It is a three-dimensional epidermoid structure exhibiting independent growth, replacing middle ear mucosa, resorbing and replacing underlying bone. Although it is not a neoplastic lesion, it can be insidious and potentially dangerous to the patient.

**Objective:** To find out the socio-demographic pattern, clinical presentation and complication of cholesteatoma.

**Materials and Methods:** This prospective study of 50 cases was done in the Department of Otolaryngology and Head-Neck surgery, CMH, Dhaka adopting simple random sampling technique from July 2008 to Dec 2009. Data were collected by personal interview and clinical examination in a pre-designed data sheet and were analyzed by SPSS 20.

**Results:** In this study, the highest number of patients (44%) was in the age group 11-20 years with a mean age of 17.2 years. Male were more affected (70%) and the male to female ratio was 2.33:1. Commonest symptom was otorrhoea (100%), followed by hearing impairment (80%), otalgia (16%), postauricular painful swelling (12%) and postauricular discharging sinus (10%). Extracranial complications were in 26% and intracranial complications in 12% of patients in this series. Abscess (temporal lobe + extra dural) were found in 02 cases (10%) by CT scan. A maximum number of patients had moderate conductive deafness (74.47%) followed by mild conductive deafness (19.15%) and only a few with severely mixed deafness (6.38%).

**Conclusion:** Clinical presentation of cholesteatoma in this study was discharge and deafness. The discharge was thick

purulent foul smelling, scanty, occasionally blood-stained. Grave intracranial complications in children developed because of illiteracy, poverty, lack of awareness and medical facilities mostly in the rural areas. So early diagnosis and prompt treatment was a necessity.

**Key-words:** Cholesteatoma, Neoplastic lesion, Clinical presentation, Complications, Socio-demographic pattern.

### Introduction

Cholesteatoma is the end stage of (squamous epithelial) retraction of the pars tensa or flaccida that are not self-cleansing, retain epithelial debris and elicit a secondary, inflammatory mucosal reaction<sup>1</sup>. A slowly progressive and destructive disease of the middle ear cleft capable of destroying soft and hard tissue surrounding it, which is a common finding in otological practice<sup>2</sup>. The attic-antral disease appears histologically with three components, the cystic content, the matrix and the perimatrix. The perimatrix layer is in contact with bone and the granulation tissue, produces various proteolytic enzymes that may result in bone destruction<sup>3</sup>. Cholesteatoma may be congenital and acquired. Again, acquired cholesteatoma may be primary and secondary<sup>4</sup>.

In three varieties of Acquired chronic active squamous otitis media (cholesteatoma) the most common form is primary acquired chronic active squamous otitis media which retained keratin debris accumulates<sup>5</sup>. Another type, the secondary acquired chronic active squamous otitis media that is retained within the middle ear, mastoid or both. Third varieties of acquired chronic active squamous otitis media where the mucosa undergoes metaplasia to squamous type<sup>6</sup>.

1. Lt Col Md Ahsanuzzaman Khan, MBBS, FCPS, MCPS, DLO, Classified Specialist in Otolaryngology and Head-Neck Surgery, CMH, Dhaka  
2. Col AKM Asaduzzaman, MBBS, FCPS, MCPS, DLO, Classified Specialist in Otolaryngology and Head-Neck Surgery, CMH, Dhaka  
3. Lt Col Md Tauhidul Islam, MBBS, FCPS, MCPS, DLO, Classified Specialist in Otolaryngology and Head-Neck Surgery, CMH, Dhaka  
4. Lt Col Bashir Ahmed, MBBS, FCPS, MCPS, DLO, Classified Specialist in Otolaryngology and Head-Neck Surgery, CMH, Dhaka  
5. Lt Col Mohammad Kamal Hossain, MBBS, FCPS, MCPS, DLO, Classified Specialist in Otolaryngology and Head-Neck Surgery, CMH, Dhaka  
6. Maj Mohammad Misbah Al Kabir Sumon, MBBS, FCPS, DLO, Classified Specialist in Otolaryngology and Head-Neck Surgery, CMH, Momenshahi  
7. Maj Sarder Mohammad Golam Rabbani, MBBS, FCPS, Classified Specialist in Otolaryngology and Head-Neck Surgery, Adhoc CMH, Ramu.

Clinical presentation of chronic active squamous otitis media (cholesteatoma) in an uncomplicated case is usually discharge and deafness, the discharge is thick purulent foul smelling, scanty, occasionally bloodstained<sup>7</sup>. This can be often asymptomatic, only discovered as an incidental finding. However, with the presence of complications patient develop earache, fever, chill and rigor, postauricular swelling, vomiting, vertigo, headache, postauricular discharging sinus, facial weakness etc<sup>8</sup>. In our country many cases with chronic active squamous otitis media (cholesteatoma) present with extracranial complication and sometimes with grave intracranial complications specially in case of children because of illiteracy, poverty, lack of awareness and lack of medical facilities mostly in the rural areas. As chronic active squamous otitis media (cholesteatoma) is considered unsafe because of the risk of complications, particularly intracranial complications, early diagnosis and treatment is essential for the safety of patients<sup>9</sup>.

Throughout the early half of the 20th century, Cholesteatoma was managed by radical mastoidectomy or exteriorization. Over the last couple of decades, otologic surgeons have migrated to a more conservative mastoidectomy approach. Most otologic surgeons now perform techniques depending on the individual circumstances of a particular patient<sup>10</sup>.

### Materials and Methods

This was a prospective study done on 50 cases adopting simple random sampling technique and was conducted in the Department of Otolaryngology and Head-Neck surgery, CMH, Dhaka, Dhaka cantonment from July 2008 to Dec 2009. The inclusion criteria for this study were chronic active squamous otitis media and exclusion criteria were mucosal otitis media, cholesteatoma, CSOM with scanty foul smelling discharge, CSOM with attic perforation.

### Results

A total of 50 cases were included in this study and, all the information were compiled and presented in the form of tables and figure as shown below.

**Table-I:** Distribution of patients by age (n=50)

Age (in years)	Number of patients	%
0-10	10	20
11-20	27	44.0
21-30	08	16.0
31-40	05	10.0
>40	0	0.0

Table-I shows that the age range of the cases studied was from 6 years to 40 years. The youngest patient presented with cholesteatoma was 6 years old and the eldest patient was 40 years old. The average age is 17.2 years. Male is more affected (70%) than female (30%). The ratio of male and female is 2.33: 1.

**Table-II:** Distribution of patients by educational status (n=50)

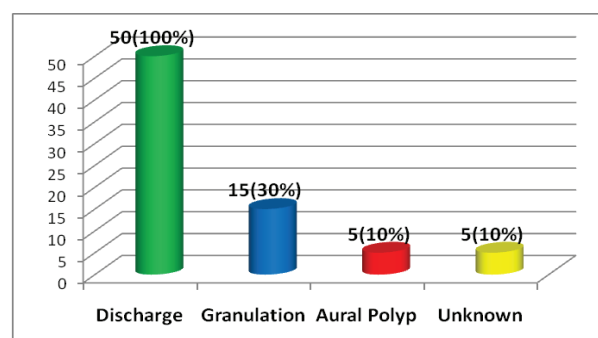
Educational status	Number of patient	%
No education	11	22
Primary education	20	40
Secondary education	09	18
Higher secondary education	06	12
Graduation	04	8

Table-II shows that the patients either having no education group (22%) or having primary education (40%) are mostly suffering from cholesteatoma (Active squamous chronic otitis media) in this series.

**Table-III:** Distribution of patients by clinical presentation (n=50)

Symptoms	Number of patient	(%)
Discharge from ear	50	100
Hearing impairment	40	80
Earache	08	16
Fleshy mass in ear	07	14
Post auricular painful swelling	06	12
Post auricular discharging sinus	05	10
Fever	05	10
Headache	05	10
Vomiting	03	06
Vertigo	02	04
Neck rigidity	02	04
Facial paralysis	01	02
Tinnitus	01	02
Imbalance	01	02

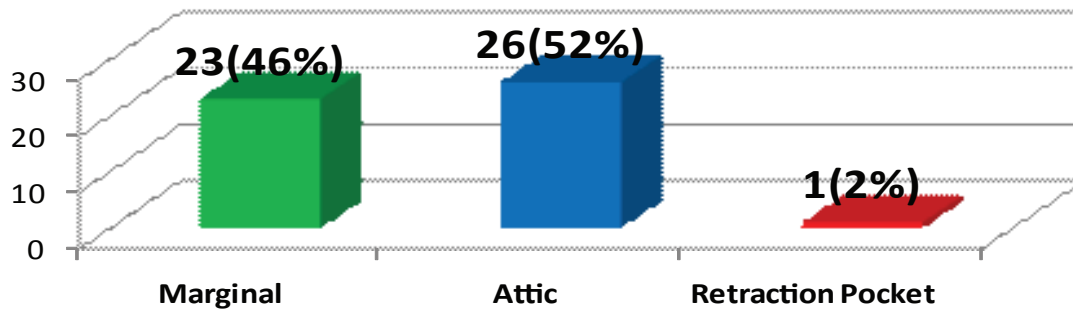
Almost all the patients presented with more than one symptom. Commonest symptoms were otorrhoea (100%), followed by hearing impairment (80%), otalgia (16%), postauricular painful swelling (12%) and postauricular discharging sinus (10%). A few patients complained about tinnitus (2%) and imbalance (2%) (Table-III).



**Fig-1:** Distribution of patients by the condition of the external auditory canal (n=50)

**Table-IV:** Distribution of patients by character of discharge (n=50 ears)

Smell		Amount		Colour	
Malodourous	Odourless	Scanty	Profuse	Blood stained	Pearly white
50	0	40	10	10	40



**Fig-2:** Distribution of patients by site of perforation and retraction pocket in attic region of tympanic membrane (n=50)

**Table-V:** Distribution of cholesteatoma (Active squamous chronic otitis media) patients by complications (n=50)

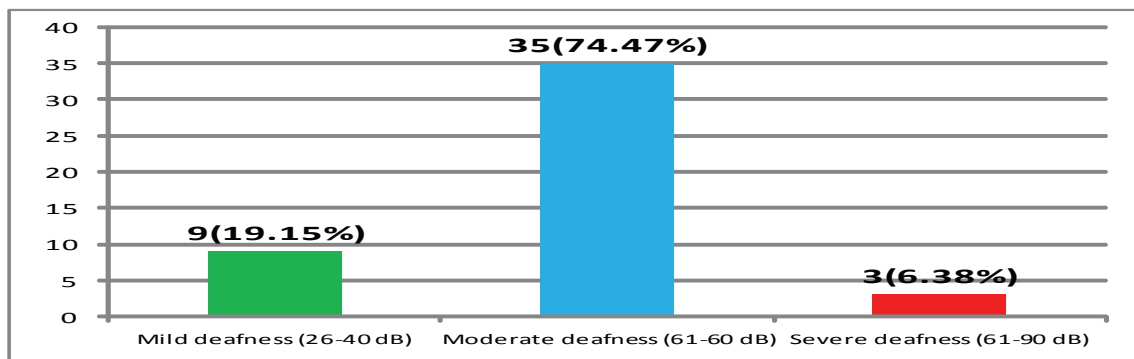
Complications	Number of patients	Percentage
Postauricular abscess	06	12
Postauricular Sinus	05	10
Facial palsy	02	04
Extradural abscess	01	02
Lateral sinus thrombophlebitis	01	02
Meningitis	03	06
Temporal lobe abscess	01	02

**Table-VI:** Distribution of patients by the site of cholesteatoma (per-operative findings) (n=49 ears)

Site and extension of cholesteatoma	Number of Ears	Percentage
Attic + Aditus + Middle ear	11	22.44
Attic + Aditus + Antrum + Middle ear	14	28.58
Attic + Aditus + Antrum + Mastoid + Middle ear	24	48.98

**Table-VII:** Distribution of patients by findings of CT scan of temporal bone and brain (n=20)

Findings	Number of Cases	%
CT scan of ear:- circumscribed cavity with ossicular erosion	18	90
CT scan of brain:-Space occupying lesion	02	10



**Fig-3:** Audiological findings of cholesteatoma (Active squamous chronic otitis media) patient (n=47 ears).

## Discussion

In this study, the highest number of cases belongs to the age group of 11-20 years (44%). The youngest patient in this series was 6 years old and the eldest patient 40 years old (Table-I). Study done by Shenoi PM and Cody TR et al found that youngest patient was 04 years old and eldest patient was 55 years old<sup>11,12</sup>. In this series, the educational status shows that most patients are from either in the illiterate group (22%) or in primary education group (40%). This reflects the higher incidence of cholesteatoma (Active squamous chronic otitis media) in illiterate and low-educated people (Table-III). Other study done by Ludman H and Chowdhury MA et al revealed that most of the patient (52%) with cholesteatoma was illiterate<sup>13,14</sup>.

Almost all the patients presented with multiple symptoms otorrhoea (100%) was the commonest symptom to present with, followed by hearing impairment (80%), otalgia (16%), some fleshy mass (14%) in the external auditory meatus, postauricular discharging sinus (10%), 26% of patients presented with extracranial complications and intracranial complications were 12% of patients (Table-VI). Study done by Kangsanarak J et al found that most of the patients (89%) were presented with ear discharge and intracranial complication (7%) which is not similar with this study<sup>15</sup>.

In this study, it is seen that cholesteatoma (Active squamous chronic otitis media) involved right ear in 56% of cases and left ear in 44%<sup>12</sup>. Otoscopic examination of middle ear shows discharge in 100% cases, granulation tissue in 15% cases and sagging down of posterosuperior canal wall in 5% cases (Figure-1). The discharge was foul smelling (100%) scanty (80%), pearly white (80%) and bloodstained (20%) (Table-VII). Ludman H found in his study that foul smelling ear discharge (98%) and granulation tissue (10%)<sup>12,13</sup>.

About the condition of the eardrum, the most common findings are perforation of the eardrum (49 ears) either in the posterosuperior marginal (46%) or in the attic (52%) (Figure-2). These findings of posterosuperior marginal perforation in eardrum are higher. Study done by Roland PS found that attic perforation 60% cases and marginal perforation 40% case which is similar to this study<sup>10</sup>. Regarding complications, it is observed in this series that only 12% cases presented with intracranial complications, three with meningitis, one with extradural abscess, one with lateral sinus thrombophlebitis and one with temporal lobe abscess. Almost one-fourth of the total cases presented

with extracranial complications, 06 with post auricular abscess and 05 with postaural discharging sinus and 02 with facial nerve palsy. Study done by Kemppainen HO et al revealed that 25% cases presented with extracranial complication. Most of them were post auricular abscess and discharging sinus which is similar to this study<sup>11,16</sup> but inconsistent with the studies<sup>17,18</sup> who found intracranial complications around 12% of Cholesteatoma (Active squamous chronic otitis media). In this series, it supports the late presentation of cholesteatoma (Active squamous chronic otitis media) in Bangladesh<sup>17,18</sup>.

Regarding the site and extension of cholesteatoma, it was found that 48.98% had involvement of the whole middle ear cleft, 28.58% had involved middle ear, attic, aditus and antrum<sup>11,16</sup>. Cholesteatoma localized in the attic, aditus and middle ear region 22.44% cases. One patient had retraction pocket with pearly white debris in pars flaccida.

This can be explained by the fact that the late presentation of cholesteatoma allows it to extend into the different parts of middle ear cleft. As per imaging X-ray mastoid Towne's and Stenver's (Table-X) view revealed well circumscribed cavity in 35 patients (70%). In CT scan of tympanomastoid region and brain (Table-XI) well circumscribed cavity in tympanomastoid region with ossicular chain erosion was found in 18 patients (90%) and abscess (temporal lobe + extradural) was found in 02 cases (10%) as per the audio logical findings maximum patients had moderate conductive type of deafness (74.47%) (Figure-3) followed by mild conductive deafness (19.15%) and a few with mixed deafness (6.38%). About surgical treatment; most of the patient had undergone modified radical mastoidectomy (91.84%). A few patient (6.12%) required radical mastoidectomy due to associated intracranial complications (Table-XII). One patient was treated conservatively by regular microscopic suction clearance with high magnification as because they were limited cholesteatoma in the attic early and positive diagnosis of cholesteatoma by clinical examination and timely intervention is imperative for the eradication of the disease and lessening its complication, thus saving thousands of lives. We suggest every practitioner should have an otoscope to screen out cholesteatoma (Active squamous chronic otitis media).

## Conclusion

Cholesteatoma is not an uncommon disease in Bangladesh. Cholesteatoma requires time to develop, being the earliest cases diagnosed at the age of 6 years and maximum age of

about 40 years in this study. Most of the patients presented with multiple symptoms with or without complications. Hearing impairment, foul smelling, scanty yellowish or bloodstained discharge of long duration are found in most patients. Cholesteatoma with complications are found in relatively low age group, residing in the rural areas in overcrowded unhygienic condition and suffering from malnutrition, illiteracy and ignorance about the primary health care are sufferers of this dreadful disease. Early and prompt diagnosis of cholesteatoma by clinical examination and timely intervention are imperative for the eradication of the disease and lessening its complication, thus saving thousands of lives.

### References

1. Browning GG, Merchant SN, Kelly G et al. Chronic otitis media. In: Gleeson M, editor. Scott-Brown's Otolaryngology, 7th ed, London. Arnold 2008; 3:3396-3401.
2. Cawthorne T. Congenital cholesteatoma. *Acta oto-rhinolaryngologica Belgica* 1971; 25(6):833-6.
3. McDonald TJ, Cody DT, Ryan Jr RE. Congenital cholesteatoma of the ear. *Annals of Otolaryngology & Rhinology* 1984; 93(6):637-40.
4. Jackler RK. The surgical anatomy of cholesteatoma. *Otolaryngologic clinics of North America* 1989; 22(5):883-96.
5. Sadé J, Shatz A. Cholesteatoma in children. *J Laryngol Otol* 1988; 102(11):1003-6.
6. Roger F. Gray, Mautice Howthorne. editors, *Synopsis of Otolaryngology* 5th ed, 1992.
7. Alan G Kerr, John B, editors. *Scott Brown's Otolaryngology, Otolaryngology* 6th edn Butterworth and Heinemann, 1997.
8. Herald Ludman Tony wright, Editors, *Disease of the ear*, 6th ed, 1998.
9. Ballenger JJ. *Disease of ear nose and throat. Head neck*, 13th ed. Philadelphia Lea and Fabiger 1985:11360-42.
10. Roland PS. Middle ear Cholesteatoma. Available at <http://emedicine.medscape.com/article/860080-overview>.
11. Sheno PM. Management of chronic suppurative otitis media. *Scott-Brown's Otolaryngology*, 6th ed. Oxford, London, Boston, Butterworth-Heinemann 1987:215-37.
12. Cody TR, Taylor WF. Mastoidectomy for acquired cholesteatoma Long term results. In: McCabe BF, Sade J, Abramson M, editors. *Cholesteatoma (Active squamous chronic otitis media)*, 1st International Conference, Birmingham, Alabama. Aesculapius Published Co 1977; 33: 51.
13. Ludman H. Complication of suppurative otitis media. Booth JB, editor. *Scott Brown's Otolaryngology*, 5th ed. London: Butterworth 1987; 3:264-91.
14. Chowdhury MA, Alauddin M. Comparative study between tubotympanic and atticofacial types of chronic suppurative otitis media. *Bangladesh Medical Research Council bulletin* 2002; 28(1):36-44.
15. Kongsanarak J, Foonant S, Ruckphaopunt K et al. Extracranial and intracranial complications of suppurative otitis media. Report of 102 cases. *The Journal of Laryngology & Otolaryngology* 1993; 107(11):999-1004.
16. Kemppainen HO, Puhakka HJ, Laippala PJ et al. Epidemiology and aetiology of middle ear cholesteatoma. *Acta oto-laryngologica* 1999; 119(5):568-72.
17. Nyrop M, Bonding P. Extensive cholesteatoma: Long-term results of three surgical techniques. *The Journal of Laryngology & Otolaryngology* 1997; 111(6):521-6.
18. Alho OP, Jokinen K, Laitakari K et al. Chronic suppurative otitis media and cholesteatoma. Vanishing diseases among Western populations?. *Clinical Otolaryngology & Allied Sciences* 1997; 22(4):358-61.